



PRESENTING CLINICAL SIGNS

History: Arrhythmia noted on 10/16/21 when in clinic for ruptured cyst exam. ECG showed intermittent APCs.

DATE

12/9/21

ECHOCARDIOGRAPHIC FINDINGS

Multiple 2D, M-mode, and Doppler video loops and still images are submitted for review.

PERFORMED BY:

Dr. Jacquie Pankatz

Left atrial size is normal. The mitral valve is normal. Left ventricular wall thickness is normal. Left ventricular internal dimensions are normal. Left ventricular systolic function is normal. The aorta and aortic valve appear normal, though there is mildly increased flow velocity in the ascending aorta. Right atrial and right ventricular dimensions are normal. The tricuspid valve is normal. The pulmonary artery and pulmonic valve are normal. No heartworms are visualized. No pericardial effusion or cardiac masses are seen.

INTERPRETED BY

Keith Blass, DVM,
MS, DACVIM
(Cardiology)

LA - 43.3 mm
IVSd - 13.0 mm
LVPWd - 13.2 mm
LVIDd - 42.7 mm
LVIDs - 26.9 mm
FS - 37%
RA - 29.3 mm
LVOT - 2.50 m/s
RVOT - 1.44 m/s

PATIENT

Indy Prescott

SPECIES

Canine

ASSESSMENT/RECOMMENDATIONS

Normal echocardiogram

BREED

This examination demonstrates no evidence of structural heart disease. As such, no reason for Indy's APCs is appreciated in the image set.

Bull Mastiff Mix

Indy does have mildly increased flow velocity in his aorta, which could potentially result in the auscultation of a left basilar functional/innocent murmur.

SEX

No therapy is recommended based on this exam.

MN

A recheck echocardiogram is recommended if new physical exam and/or clinical abnormalities suggestive of structural heart disease develop.

AGE

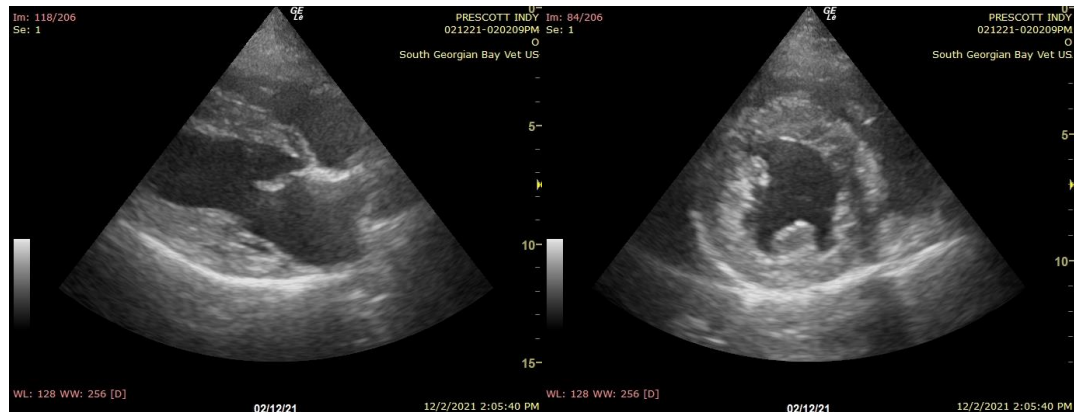
8 y

WEIGHT

49 kg

HOSPITAL NAME

Mountain Vista VH



REFERRING VET

Dr. Pankatz



DATE

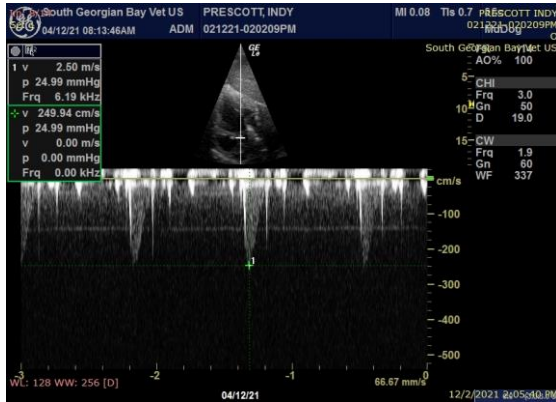
12/9/21

PERFORMED BY:

Dr. Jacquie Pankatz

INTERPRETED BY

Keith Blass, DVM,
MS, DACVIM
(Cardiology)



The information and recommendations provided are based on the images presented by the referring veterinarian. No evaluation can be communicated regarding pathology that was not visible in the image/video clips provided.

Thank you for this referral. If the clinical or image interpretation does not parallel your findings or if I can be of any further assistance please contact me.

PATIENT

Indy Prescott

Keith Blass, DVM, MS, DACVIM (Cardiology)
KeithBlass@gmail.com
631-804-5754

SPECIES

Canine

BREED

Bull Mastiff Mix

SEX

MN

AGE

8 y

WEIGHT

49 kg

HOSPITAL NAME

Mountain Vista VH

REFERRING VET

Dr. Pankatz